

## CHAPTER 3

### SPECIAL AND DIFFICULT FISTULAS

Section 3.1: Small and pinhole fistulas
Section 3.2: High Fistulas: Vesico-uterine fistulas
Section 3.3: High Fistulas: Vault fistulas
Section 3.4: VVF with ureter outside of the bladder
Section 3.5: Fistulas with bladder stones
Section 3.6: Double VVF
Section 3.7: Recurrent pinhole fistula
Section 3.8: Around the corner fistula
Section 3.9: Genital fistulas following radiotherapy

**⚠ Top Tip!** Even if a fistula is small and in the midline or lateral, it is a good idea to reflect the whole anterior vaginal skin bilaterally. This allows more options when closing the defect and may allow a good intermediate layer to be developed. This applies particularly to fistulas described in section 3.1, 3.7 and 3.8.

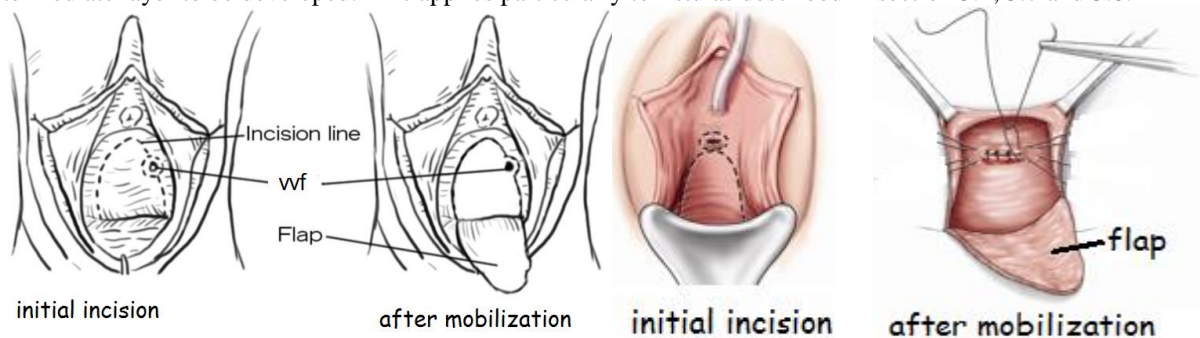


Fig. 3.1a: A wide transverse or inverted U can be used for most small fistulas which may be midline or lateral.

#### (3.1) SMALL AND PINHOLE FISTULAS

With a small fistula (< 1 cm) or pinhole (1-2 mm) in the mid-vagina or near the cervix, it may be difficult to see the ureters. If the sutures are placed too deep in the bladder wall, there is a risk of ligating or injuring the ureters. You are much less likely to ligate or injure the ureters with superficial bites of the bladder. These superficial bites of the bladder should incorporate the pubo-cervical fascia to ensure the suture does not pull out. These bites in the pubo-cervical fascia will provide an anchor of support and not endanger the ureters. Remember that the ureters run in the layer between the fascia and the bladder.

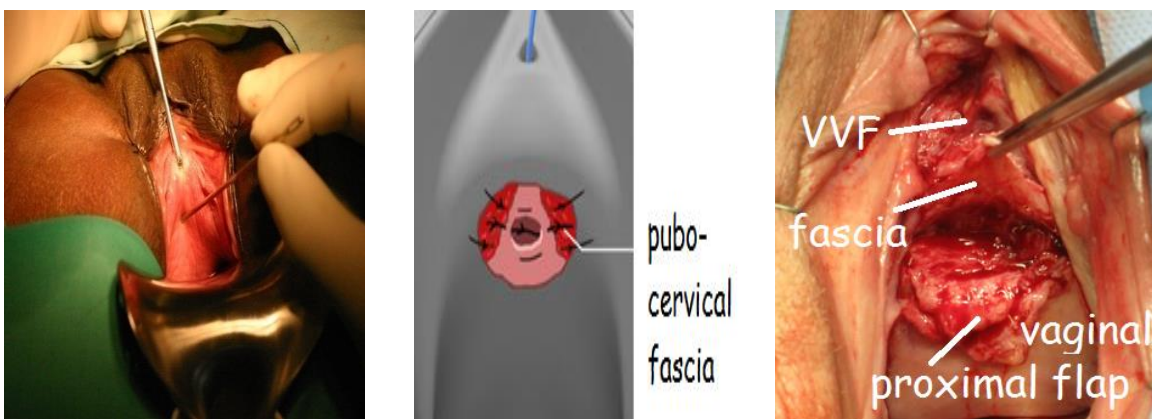

Fig. 3.1b: Shows a pinhole fistula with a probe being inserted into it.

Fig.3.1c: Shows closure of a pinhole fistula longitudinally. For clarity, the fistula is shown in the diagram larger than it would be.

Fig. 3.1d: In cases where the fascia is not used during the closure of the VVF, after the VVF has been closed, where possible, the pubo-cervical fascia (held by forceps) is dissected off the proximal flap of vagina and used as an additional layer for the repair by stitching it to the periosteum on either side of the urethral opening distal to the fistula. See Fig. 6.4c for a diagrammatic representation of this procedure.

**Dissection of the vagina off the bladder:** Even though the fistula is small, you still need a wide exposure to allow proper closure (see Fig. 3.1a) utilizing the pubo-cervical fascia which is mobilized from the vaginal skin.

**Tip!** Keep a narrow metal catheter or probe in the fistula while you dissect and close it so that you do not lose sight of the lumen.

**Closure:**

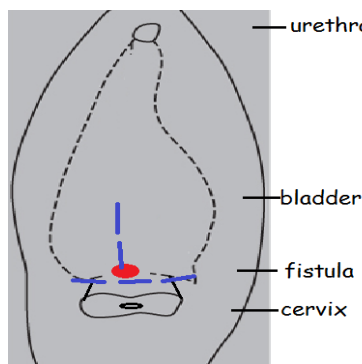
- (a) *Transverse closure:* You may close the pinhole fistula transversely in the standard method  $\pm$  incorporating the pubo-cervical fascia. Most of the bites are in the fascia rather than the bladder to avoid the ureters. If you close the pubo-cervical fascia separately (Fig. 3.1d), it can be re-attached to the periosteum in a transverse direction (Fig. 3.1d and 6.4c).
- (b) *Longitudinal closure:* Usually only three stitches are needed for closure of the fistula. Each suture is placed first and only tied when all three are placed (Fig. 3.1c).
- Place the first stitch proximal to the fistula. Take a deep bite of fascia, superficial bite of bladder close to one side of the fistula, superficial bite of bladder close to the other side of the fistula and finally a deep bite of fascia.
  - The second stitch is placed in the same way at the distal end of the fistula.
  - The third stitch is placed in the same way between these two.

Some surgeons avoid stitches through the bladder wall and only take bites of the fascia on either side of the fistula. As the fascia is adherent to the bladder, the fistula should close as you approximate the fascia.

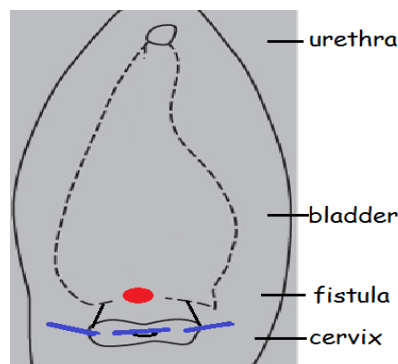
**Tip!** You may also give frusemide to make sure there are no spurts of urine close to the edge, or ensure urine is still coming from the right or the left side after each bite. However, this cannot be done with true pinholes.

### (3.2) HIGH FISTULAS: VESICO-CERVICAL/ UTERINE FISTULAS

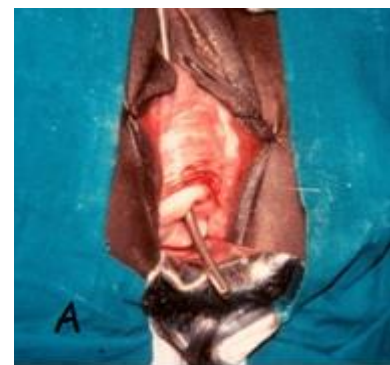
Vesico-cervical or uterine fistulas may follow Caesarean section or sub-total hysterectomy. It may not always be clear from the history which was done as some menstruation may still occur from the uterine stump. As these are high fistulas, it may be easier to approach them abdominally. However, once demonstrated, the vaginal approach is not difficult in most cases.



*Fig. 3.1e: Shows the approach of finding the fistula by dissecting between the bladder and the cervix. The fistula site is in red. Incision is in blue.*



*Fig. 3.1f: Shows the approach of finding the fistula by splitting the cervix open with a transverse incision. The fistula site is in red. Incision is in blue.*



*Fig. 3.2a: Shows a sound coming out through the cervix, indicating a vesico-uterine fistula. With a good cervix, the approach used would be as in Fig. 3.1e.*

**Diagnosis**

- If dye is injected into the bladder, it comes out through the cervix. It sometimes helps to pass a metal catheter through the cervical canal into the uterus so that the urine or dye flows out of the cervical os more easily.
- It may sometimes be possible to see the fistula. Pull the anterior lip of the cervix up with a long Allis forceps which may make the track easier to see. Pass the metal catheter up the canal to retract the posterior wall of the cervix and expose the anterior wall so that any fistula of the cervix can be seen.
- Try to pass a (uterine) sound or metal catheter into the bladder via the urethra and then locate the opening in the anterior part of the cervix (as seen in Fig. 3.2a). If the hole is pin-point, this test may not work. Therefore always examine carefully vaginally, repeating the dye test if necessary.

**Repair:** There are two approaches to vaginal repair:

- Work from above the cervix (supra-cervical or between the cervix and the bladder as in Fig. 3.1e): This approach is preferred where possible. It is much easier to use this method if the anterior lip of the cervix is normal. It can be used when the dye test is positive but you cannot pass a probe from the urethra/ bladder down into the fistula.
- Work from inside the cervix (intra-cervical or through the cervix as in Fig. 3.1f) by splitting the cervix to make access to the fistula much easier. One of the advantages of this method is that it is easy to do even if the anterior cervix is scarred or torn. This method can only be used when a probe (metal catheter or uterine sound is best) can be passed from the urethra/ bladder down into the fistula.

Which approach you use depends on:

- How torn or scarred the anterior cervix is: if torn or irregular Method 2 is easier.
- Whether a probe can be passed through the fistula: If it can, Method 1 or 2 is possible. If it cannot, then Method 1 is possible although you may have to switch to an abdominal approach if it fails.
- If the cervix is pulled up in the vagina and cannot be pulled down, you may have to use the extra-peritoneal supra-pubic approach. This may also apply if the patient is very obese and access is difficult.

**! Tip!** In general, if you can pass the sound through the cervix, the fistula repair should be accessible from a vaginal approach. To pass the sound or probe, you may have to use your left hand in the vagina to feel for the probe and to guide it into the fistula opening. If a sound cannot be passed through the cervix, it may or may not be possible to repair vaginally. In these cases, a suprapubic approach may be needed, especially if the fistula is high in the bladder or for those not familiar with the vaginal approach (Method 1 below).

**High fistula i.e. not visible initially:** Try to pass probe via urethra out through the fistula/ cervix

**Probe does not pass:** Can either be a low cervical fistula (vaginal route possible using Method 1 below) or a high cervical/ uterine fistula (suprapubic approach only).

**Probe passes:** Vaginal approach usually possible. If it fails, then switch to suprapubic approach.

#### (METHOD 1) WORKING FROM ABOVE THE CERVIX (SUPRA-CERVICAL APPROACH)



Fig. 3.2b: Shows the incision to dissect the vagina off the cervix and bladder.

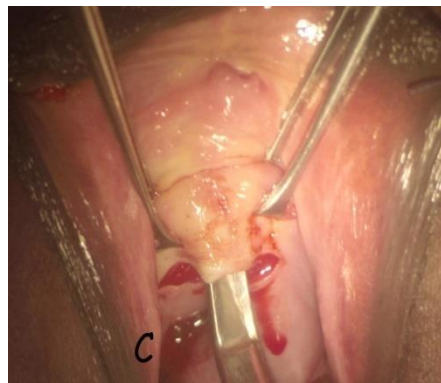

Fig. 3.2c: Shows the transverse incision made and the vagina is being undermined with scissors for the vertical extension.

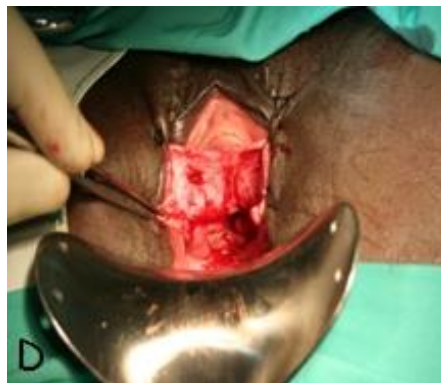

Fig. 3.2d: Shows the vaginal flaps sutured back for exposure.

This is similar to dissection for a vaginal hysterectomy i.e. dissecting the bladder off the cervix/ uterus.

- Holding the cervix, make a transverse incision about 1-2 cm above the os or along the upper border of the cervix.
- A vertical incision is added (Fig. 3.2b) which allows you to develop two flaps of the vagina, which are then stitched back laterally to give good exposure (see Fig. 3.2d). There are two options for making the vertical incision:
  - (a) With scissors, if access is good: introduce the tips of the scissors upwards in the midline from the transverse incision and spread the tips (Fig. 3.2c). This undermines the vagina which is then cut.
  - (b) With a knife, if access is poor or the tissues are scarred.
- During this dissection, an Allis or vulsellum forceps is applied to the cervix to pull downwards and posteriorly while the bladder is pulled upwards and anteriorly with a second Allis forceps. Stay in the

midline and close to the cervix until you find the fistula (distal end) i.e. you see the dye coming out. The fistula will be where the bladder is stuck onto the cervix/ uterus. If the metal catheter (from the urethra) passes into the fistula, this can assist in finding the fistula site. Once found, hold the fistula's distal bladder edge with an Allis and pull upwards.

- Free around the fistula circumferentially between the bladder and cervix until the proximal end is free. This is done by applying an Allis forceps on each side to provide gentle traction. Once there is enough mobilization, place a Langenbeck retractor or a Sims speculum inside the fistula to help expose the proximal end (Fig. 3.3d + e). Often the fistula opens up and becomes quite large when released from the surrounding tissue.
- The proximal edge is dissected until the edges are free.
- The ureters are usually in the distal flap and may have to be catheterized. They are never far away!

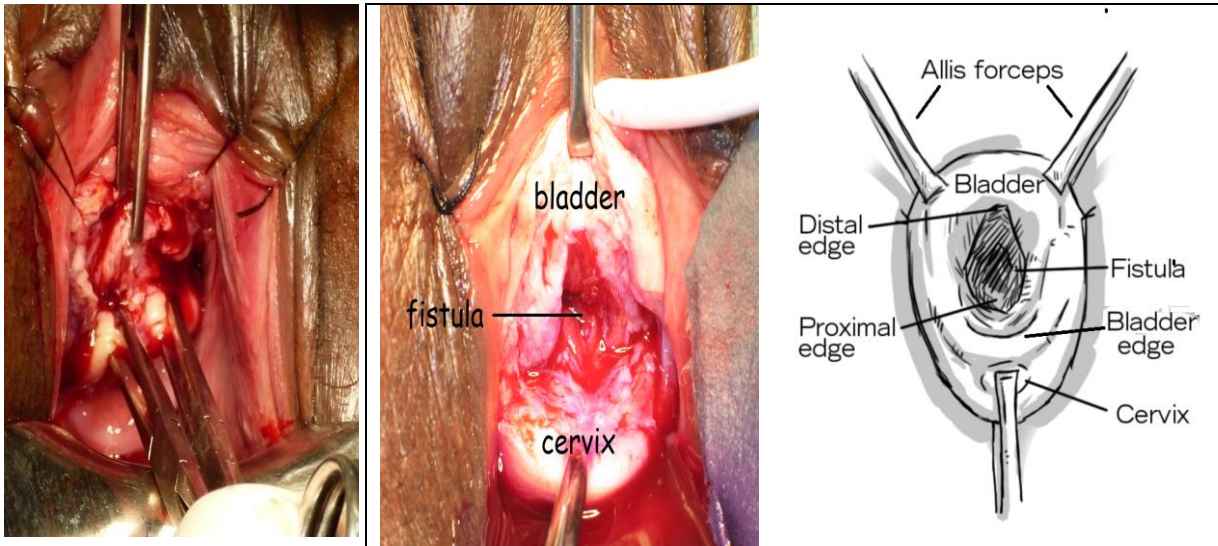



Fig 3.3a: The bladder is lifted by traction with a single Allis forceps while counter-traction is placed on the cervix with two Allis forceps.

Fig. 3.3b+c: By dissecting between the bladder and cervix, the fistula will open (urine/ dye or bladder mucosa seen as in this case). The fistula can then be held with Allis forceps. Initially hold the distal edge, then the lateral edges and eventually the proximal edge as you dissect between the bladder and the cervix.

	<p>Make sure the tips of the scissors are facing towards the cervix and not the bladder as you dissect. This will reduce the risk of injury to the bladder. Also, remember to stay close to the cervix as you dissect.</p>
---	--

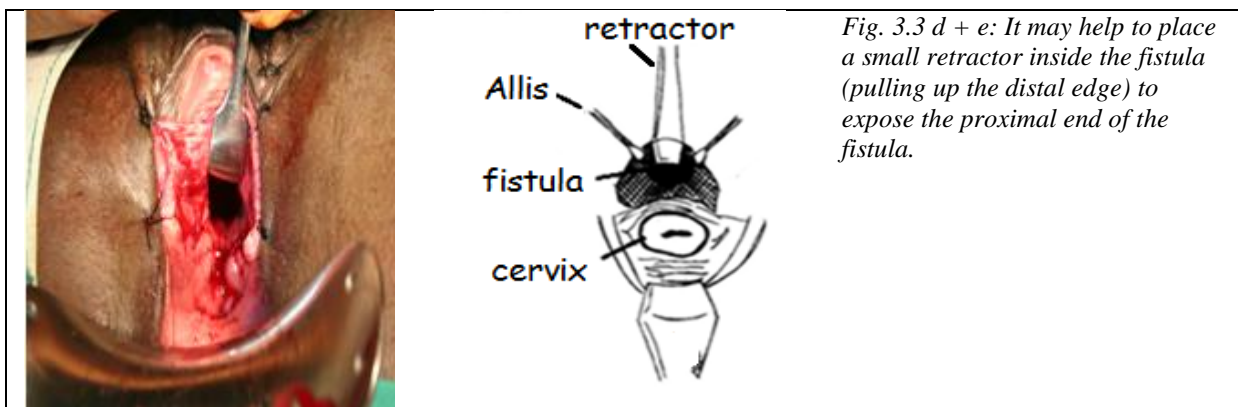


Fig. 3.3 d + e: It may help to place a small retractor inside the fistula (pulling up the distal edge) to expose the proximal end of the fistula.

- The closure is the same as for any fistula and is usually done transversely although it may be easier in some cases to repair it longitudinally (see section 3.3 on vault fistulas as the closure is often similar).
- You should usually repair the hole in the uterus/ cervix now. However, often there is no visible or palpable anterior cervix. If you are able to bring the sides of the cervix together in the midline after dissection, you can close the cervix over a small suction tubing or Foley catheter (8-14 Fr) placed in the cervical canal and leave this in the cervix for 7-14 days after surgery (see also Method 2 below).

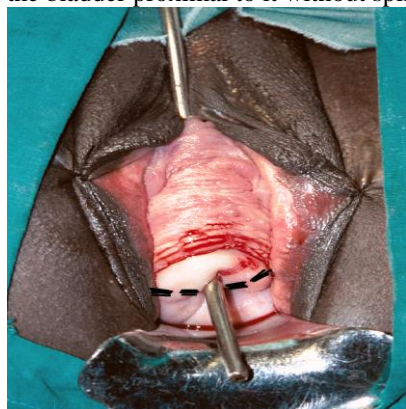Using this method, you can do most high fistulas vaginally that are initially not visible. However, an abdominal approach may be required if: (a) The cervix is pulled up out of sight so that you cannot make the initial incision. (b) When trying a vaginal approach you find the fistula extends up to the fundus of the bladder.

**(METHOD 2) WORK FROM INSIDE THE CERVIX (INTRA-CERVICAL APPROACH)**

A probe must be passed down from the urethra/ bladder into the fistula before you can attempt this method.

**Overview:** This method is difficult to describe because in most cases you cannot see the fistula initially. You can only see the probe. The key to understanding this method is the lateral incisions which are made deep on each side at 3 and 9 o'clock into the cervix (see Fig. 3.1f and Fig. 3.4). As these are made, the cervical canal opens up and the fistula becomes visible. Then you can make the distal and proximal incisions around the fistula. The rest of the procedure is the same as with any fistula repair. Remember to use steep head-down position with the patient's buttocks over the table edge.

**Incision:** In some cases, it may be possible to grasp the proximal lip of the fistula with an Allis and mobilize the bladder proximal to it without splitting the cervix.



However, in most cases, with the probe in the fistula, it is necessary to make a transverse incision through the cervix on either side of the fistula for exposure (Fig. 3.4). It is easiest to think that the incisions that cut the cervix are the usual lateral extensions except they go deeper (into the cervical tissue) than usual. This splits the cervix open transversely.

The incision in the cervix is best made with cautery to reduce the amount of bleeding although severe bleeding is unusual. Be careful not to go too lateral with the incision as the ureter lies just lateral to the cervix.

After making these lateral incisions, keep the probe in the fistula to retract as you incise around the probe (distal and proximal incisions).

Fig. 3.4: Shows the two lateral incisions (black dotted lines) made into the cervix.

**Dissection:** Once the incision is made, dissect distally, proximally and laterally in the same way as for any fistula.

- Distally: Mobilize the vagina off the bladder, so that you can stitch the distal vagina back with stay sutures for exposure. Be extra careful to stay close to the vagina to avoid opening the bladder. One way of doing this is to put your finger behind the vaginal flap and cut close to (your finger and) the vagina. It is not usually possible to find the ureters until the vagina is mobilized as the ureters are usually on the distal margin of the fistula. Often the anterior lip of the cervix is destroyed so be careful not to cut the bladder.
- Proximally: Put an Allis forceps on the proximal and lateral lips of the fistula and pull on these as you dissect the bladder off the vagina and cervix.



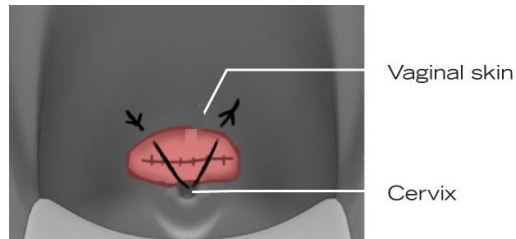
Tip! To help find the ureters on the distal margin, place two Allis forceps on the edges and pull distally.

**Closure:**

- Bladder: Close the bladder in a transverse direction usually although some surgeons close it longitudinally. Confirm adequate closure with dye test.
- Cervix: Because the cervix was split or was torn anteriorly, to reform it:
  - Place a suction tubing 14-18 F in the cervical canal. The cervix is reformed over this tube.
  - Take deep transverse bites of the cervical tissue on either side of the tubing (right and left) and tie. Usually 2-3 sutures are needed to bring the cervix back together.
  - Leave the tubing in the cervical canal for 7-14 days or ideally until the next menses to prevent cervical stenosis. To prevent it falling out, first the tubing should be transfixed with an absorbable suture and then the suture is fixed to the vaginal wall.

**Vagina:**

- First, close the lateral vaginal angles.
- Then close the midline. The tubing in the cervix should protect against closing the cervix. A midline stitch brings the anterior vaginal skin down to the cervix (Fig 3.5).
- Then fill in any gaps between the lateral and midline sutures.



*Fig 3.5: Shows the closure of the vagina to the cervix. It is important to avoid the cervical os being closed over as that would lead to haematometria.*

### (3.3) HIGH FISTULAS: VAULT FISTULAS

These occur post-hysterectomy, most commonly when performed for a ruptured uterus. The fistula is usually located on the anterior vaginal wall just proximal to the inter-ureteric ridge (trigone). For repair, either use the standard or Latzko method:

#### STANDARD (FLAP SPLITTING) METHOD

If possible, first catheterize the ureters through the fistula opening. They are usually on the distal margin of the fistula and are often close to the edge. The metal catheter is useful to display the inside of the bladder. If you cannot see the ureters, you may have to start the dissection first.

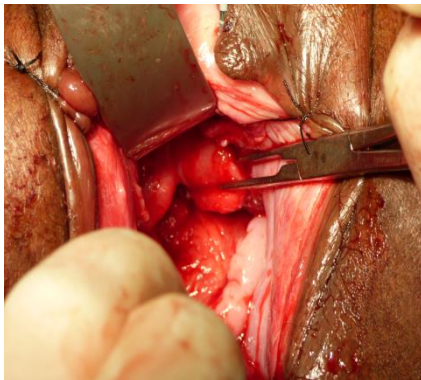
**Incision + Dissection:** The standard incision is made as in chapter 1. The vagina is dissected from the bladder. Remember to hold both the vaginal and bladder edges with forceps as you cut, as this makes access easier. Once mobilized, stitching back the vagina both distally and proximally will reduce the need for retraction of the edges by the assistants.

**Tip!** Mobilization of the fistula proximally is often facilitated by deliberately opening the peritoneal cavity into the pouch of Douglas behind the fistula. Some surgeons prefer to close the peritoneal opening later so that the blood, urine or dye does not wash into the abdomen with the patient in Trendelenburg position. However, this is not essential and it is easier to incorporate it into the vaginal closure.

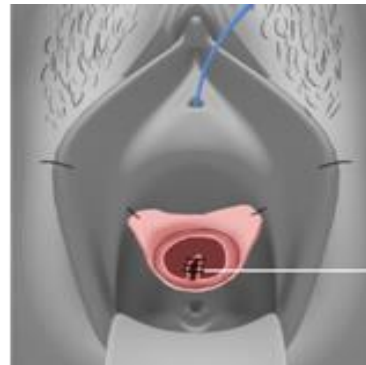
**Reference:** *Vesico-vaginal Fistulas in Developing Countries: Paul Hilton in Textbook of Perinatal Medicine (2<sup>nd</sup> edition 2006). Chapter 201 Editors: Kurjak A and Chervenak FA. CRC Press.*



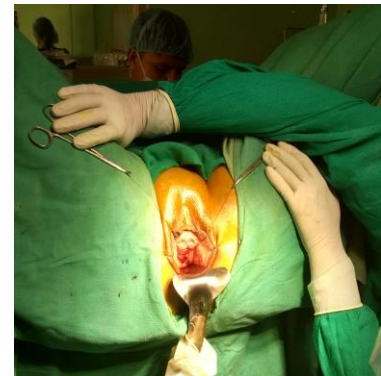Even though the ureters open distally into the bladder, you can still injure them during proximal dissection especially if there is a lot of scarring from the original surgery.



*Fig. 3.6: Shows an extension or tear in the proximal wall. The proximal bladder is being held with Allis forceps to demonstrate the apex of the tear.*



*Fig. 3.7a: Shows the extension (white line) sutured with interrupted sutures from inside the bladder.*



*Fig. 3.7b: Shows the assistant stretching both angle sutures of the bladder with both hands to help in the closure of the bladder.*

**Closure:** The bladder is closed in one layer usually transversely although some surgeons prefer longitudinal closure. It helps in the exposure if you get your assistant to hold and stretch both angle sutures to display the rest of the bladder (see Fig. 3.7b).

**Extensions:** Often with vault or vesico-uterine fistulas, the margins are irregular and there may be an extension of the fistula up the proximal bladder wall (Fig. 3.6 and 3.7a). This extension can be stitched first with interrupted sutures. There are several tips in dealing with these extensions:

- Place a Sims speculum or a small Deaver retractor into the bladder to retract the distal bladder wall (see Fig. 3.6).
- Closure is done longitudinally with interrupted stitches placed from inside the bladder so the knots end up inside the bladder lumen. The alternative is to place the stitches extra-mucosally by using a backhand grip as you place the stitches so the knots end up outside. It is not critical which method is used.
- After tying, keep the short ends of each stitch on artery forceps. Upward traction on these will help place the next stitch. When stitching longitudinally, it is easy to leave gaps between stitches so check for this.
- Once the extension is closed, you may either continue with a longitudinal repair (more commonly) or complete the closure transversely depending on the fistula shape.

### THE LATZKO METHOD

This technique is useful if access is difficult. There is little, if any, shortening of the vagina from the procedure. This technique is easier than the standard method with minimal blood loss and is often used by those not so familiar to fistula surgery. The essential difference (in theory) with this method is that the sutures are placed in the fascia between the vagina and bladder rather than in the bladder and so there should be less risk to the ureters.

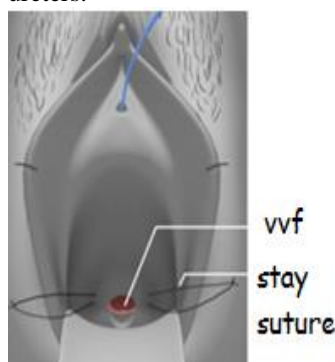


Fig. 3.8: Shows a stay suture inserted for exposure.

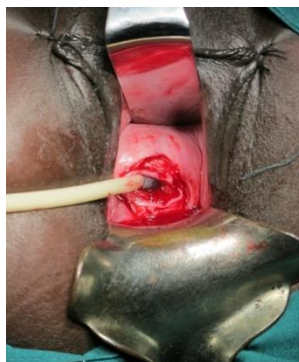

Fig. 3.9c: Shows a Foley catheter inserted into VVF.

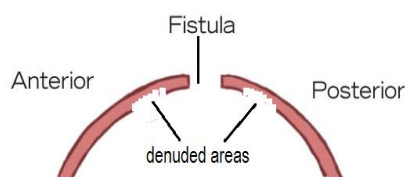


Fig. 3.9b: Shows that in a Latzko repair the anterior and posterior walls (denuded areas) of the vagina/ bladder are sutured together.

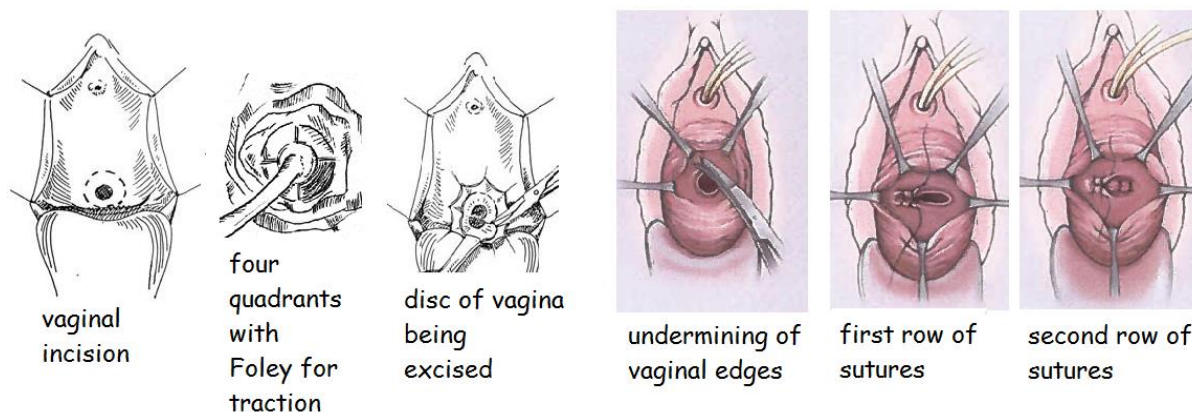


Fig. 3.9a: Shows the steps for Latzko repair.

#### For exposure:

- Use a Foley balloon to pull down and expose the fistula. The catheter is passed via the vagina into the fistula lumen and inflated (Fig. 3.9c). This allows you to make the incisions in the vagina easily. Vault fistulas are the only uro-genital fistulas where this technique is useful as there is sufficient mobility. A silastic catheter may be easier to insert as it is firmer.
- Insert two stay sutures about 3 cm from the fistula edge on each side to the lateral wall of the vagina as in Fig. 3.8.
- Injecting saline with adrenaline just beneath the vaginal mucosa facilitates dissection in the proper plane and reduces bleeding.

**Incision:** Make an outer circular incision in the vagina 1.5-2 cm from the fistula edge as shown in Fig. 3.9a. The incision should only be deep enough to go through the vaginal skin. The circular area is now divided into four quadrants (see Fig. 3.9a) and each quadrant is dissected separately and the vaginal epithelium is excised superficially. This leaves an underlying (raw) submucosal area which will be later used in the closure.

**Dissection:** After excising the vaginal epithelium, mobilize from the incision outwards by undermining the vaginal edges to develop as much fascia as possible. The scarred bladder edge of the fistula is not freshened or trimmed as this predisposes to haematoma formation.

**Closure:** All layers are closed in a transverse direction (Fig. 3.9a). The first and second layers bring together the fascia between the vagina and bladder, rather than the bladder itself and thus (in theory) avoids the ureters.

- 1<sup>st</sup> layer: the raw areas on the anterior and posterior walls are sutured together transversely. All sutures can be placed before tying them (after removing the catheter). The bites are taken just ½ cm from the edge of the fistula and do not go deep. Avoid taking bites of the bladder edge. Do a dye test after the first layer is closed. If the first layer of closure is watertight, the chance of success is good.
- 2<sup>nd</sup> layer: approximates the remainder of the raw surface of the anterior and posterior walls. The bites are taken close to the vaginal incision and should not be too deep either.
- 3<sup>rd</sup> layer: approximates the vaginal epithelium.

A combination of the Latzko with the standard method of fistula repair can be used. Use either: the Latzko incision and excise the vaginal epithelium or use the standard incision. You may then catheterize the ureters if they are close to the edge and proceed to repair the bladder as with the standard repair.

#### SUMMARY OF TIPS FOR MANAGING HIGH FISTULAS: VAULT AND VESICO-UTERINE

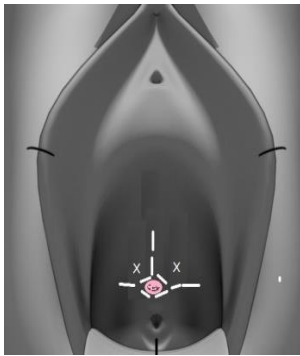



Fig. 3.9d: Shows the incision used to mobilize the vagina in proximal fistulas.

- It may help to make a midline extension when incising the vagina to help mobilize the vagina (Fig. 3.9d). Then grasp the junctions of the vertical and horizontal incisions (marked X in Fig. 3.9d) with an Allis forceps to help mobilize the vagina.
- A small Sims speculum or a small Deaver retractor can be useful for retraction of the anterior or lateral vaginal wall as you mobilize the vagina. It can later be used to retract the distal bladder wall.
- A large Deaver retractor is very useful especially in large patients to retract the posterior vagina/ cervix.
- When closing the bladder, keep the ends of the angle sutures long and place them on either side of the Auvard weighted speculum for retraction or get your assistant to stretch them (Fig. 3.7b). This traction helps to expose the remaining defect in the bladder and by placing the suture ends lateral to the speculum, they do not get in the way.

 <b>Top Tips!</b>	<p>As these fistulas are high, it can be difficult to keep sight of the proximal edges of the fistula during closure.</p> <ul style="list-style-type: none"> <li>• A great tip is to use a metal catheter inserted into the fistula to find the edges. Then (a) If you still cannot see the complete edges clearly, apply Allis forceps to hold the edges securely. (b) If you can see the edges clearly, the metal catheter can be used while you place the central sutures as the defect becomes smaller instead of pickups/ dissecting forceps.</li> <li>• As you close, keep the short end of the previous suture on an artery forceps.</li> </ul>
---	--

#### (3.4) VVF WITH THE URETER AT THE EDGE OF/ OR OUTSIDE THE BLADDER

In larger VVFs, the ureter may be at the edge of, or outside the bladder.


- If the ureter is close to the edge (Fig. 3.10): When the initial incision is made to separate the vagina from the bladder, the ureter is re-incorporated back into the bladder by incising the vagina lateral to the ureteric orifice so that the ureter becomes part of the bladder as shown with the dotted line in Fig 3.10.
- If the ureter opens away from the edge as shown in Fig 3.11 but it is still on the surface of the bladder wall and within 2 cm of the fistula, then it is usually possible to get it back into the bladder.
- If you cannot catheterize the ureter or it is stuck in scar tissue in the pelvic side-wall or you fail for any other reason, then abdominal re-implantation is necessary.
- The method you use depends very much on the situation. Therefore it is good to know all the methods. The following methods can also be used if the ureter is transected during dissection.

**Method 1 (Wrap):** Always put a ureteric catheter into the ureter first and bring it out via the urethra. This has the effect of pulling the ureter back into the bladder.

- A small amount of mobilization of the ureter may also be possible. The ureter has a rich blood supply in the adventitia so ensure that there is adequate peri-ureteric tissue if you mobilize.



- If the ureter is back from the edge of the fistula, split the bladder wall/ fistula opening down to the ureter – usually not more than 2 cm. In some cases, the ureter will be almost level with the fistula so that it is not necessary to split the bladder.
- It is then necessary in most cases to suture the ureter up to the edge of the fistula. The aim is to get the epithelia of the bladder down to the epithelia of the ureter and therefore reduce the risk of stricture. Using a fine suture of 4/0, the sutures are inserted from the ureter into the bladder to pull the ureter towards the bladder. One of these sutures is shown in Fig. 3.11a. The first bite goes from out to in (on the ureter), the second bite goes from in to out (on the bladder) and tie so the knot is outside. Start the sutures on the ureter about 3-5 mm from the edge. Alternatively, it may be easier to start with the bladder and then go to the ureter, depending which side it is. Four sutures will be placed circumferentially on the ureter (see Fig. 3.11b):
  - Place one posteriorly first and tie it. It is a good idea to (trans)fix the ureteric catheter to the bladder mucosa now as it can be very difficult to get it back into the ureter if it comes out later.
  - Then place two laterally: insert both lateral stitches before you tie. The ureter should now be pulled up to the bladder edge.
  - Place and tie the anterior stitch: this really covers the top of the ureter with the bladder and does not go into the bladder lumen i.e. bite outside of bladder on one side, then ureter wall and then outside of bladder on the other side.

	<p>Make sure the ureteric catheter is moving freely after you have inserted these sutures. If it moves but not freely, then the ureter is likely to become obstructed when the ureteric catheter is removed. In this situation, your bites have to be taken further back from the edge of the ureter.</p>
---	---

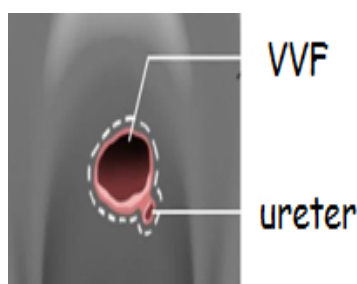


Fig. 3.10: Shows a ureter just outside the fistula/ bladder edge.

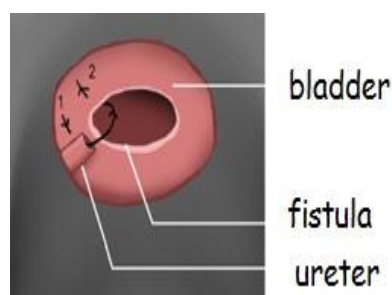
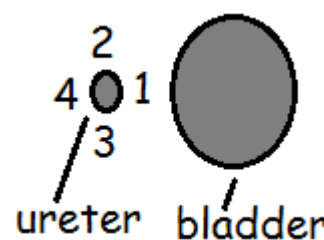


Fig 3.11: Re-setting the ureter back into the bladder as in Method 1.

Fig. 3.11a: Shows one of the lateral stitches being placed in the ureter.

Fig. 3.11b: Shows the site of the four stitches 1= posterior stitch; 2+3= lateral stitches; 4= anterior stitch.



**Method 2** (pull through): When the ureter is away (> 2 cm) from the fistula edge, an alternative option is to mobilize the ureter and then with a stab incision pull the ureter into the bladder using the same technique as you do when re-implanting abdominally. (A similar technique is described in chapter 9 under ectopic ureter.) This method only works well if the bladder has some mobility and is of a reasonable size.

- Mobilize the ureter as little as possible - about 2 cm. You can get nasty bleeders if you go up too far on the lateral pelvic wall. Catheterize the ureter. Place a stay suture on the exposed edge of the ureter. Alternatively, place four stay sutures on each quadrant of the ureter as these can help visualize the ureteric edges once the ureter is pulled through into the bladder.
- Make a hole through the bladder wall by pushing through a right-angled clamp, artery forceps or metal catheter (passed from inside the bladder).
- Grasp the ureteric catheter together with the stay stitch(es) and pull it into the bladder. The ureteric catheter is brought out through the urethra. Alternatively, this can be done in two steps i.e. the ureteric catheter can be pulled into the bladder first and then the stitch(es) on the ureter although sometimes it is difficult to follow the same hole again.
- Stitch the ureter in place (a) from the inside of the bladder with four stitches (b) from the outside of the bladder with 2-3 stitches of fine delayed absorbable sutures going from the ureter to the bladder muscle. If you can get a good closure from the inside, the outside sutures can be omitted. But if you fail to get four quadrant sutures from the inside, then you should place sutures from the outside as well.

**Method 3:** In this situation, the ureter is partially exposed by a torn bladder wall. In this situation, it is possible to close the bladder wall over the ureter/ ureteric catheter. It would be advisable to keep the ureteric catheter in place for four weeks to reduce the risk of any stenosis.

*Post-operative Care:*

- The ureteric catheter is left in for 14 days. The main purpose of it is to bypass any oedema that develops.
- Consider a renal ultrasound before discharge to check for hydronephrosis in case stenosis develops after re-implanting the ureter. However, you must consider that hydronephrosis may have been present before surgery. In addition, hydronephrosis will often be seen after re-implantation if the orifice is freely refluxing but not obstructed. Symptomatic obstruction (i.e. renal angle pain, fever) is more significant.

***If re-implantation is not possible vaginally:***

If there is wide separation of the ureter from the bladder and it is not possible to mobilize the bladder, only the fistula repaired. The ureter can be re-implanted into the bladder by an abdominal approach either then or later. The advantages of waiting until later are:

- You can see if the VVF has healed. If it has not healed, the VVF may be repaired abdominally at the same time as ureteric re-implantation.
- The bladder is often small and scarred with limited mobility which requires extensive mobilization from above in order to re-implant the ureter off tension. This mobilization may place tension on your repair that you performed vaginally and potentially increase the failure rate of the fistula repair. If in doubt, consider a staged repair and be sure to tell the patient she will still be leaking (from the ureter).

*To avoid blockage of the ureter as you close the vagina:*

- If the ureter can be catheterized, the catheter is brought out separately through the vagina. It is a good idea to use an infant feeding tube which can be transfixed with a suture to the vagina as the normal ureteric catheters have a much higher chance of falling out. Leave in the catheter for 10-14 days.
- If the ureter cannot be catheterized, then you will need to leave an opening or a drain in the vagina for the urine to flow freely post-operatively. Otherwise you may obstruct the flow of urine.

**(3.5) FISTULAS WITH BLADDER STONES**

Stones cause two problems in relation to fistula repair:

- The bladder wall may be friable, which increases the risk of breakdown.
- The risk of post-operative sepsis would be high as the urine is often purulent or offensive. Oedema of the bladder mucosa is another sign of bladder infection.

It is important to sound the bladder for stones before starting any fistula operation. If stones are found, there are two options:

- It is safest to remove the stone before any repair. Repair should only be attempted at least one week and preferably 2-4 weeks after the stone is removed.
- If you only find a stone after you have already started operating, then it would be appropriate to continue the operation after you remove the stone. There is also a more recent trend to remove stones and repair the VVF at the same time (see below). The steps to avoid infection or failure of repair in these cases are described below.

**REMOVAL OF STONES BEFORE VVF REPAIR**

- If the stone is small, it can be removed through the fistula. If necessary, you can crush the stone with an ovum forceps and remove it in pieces. The alternative is to pass your finger into the fistula and with your other hand supra-pubically, squeeze the stone out through the fistula. Then pass your finger back in, to check the bladder is empty. The bladder should be irrigated with saline to remove any fragments of stone. If you leave any small pieces inside, another stone will re-form.
- If the stone is large or the fistula is small or healed, it can be removed by making an incision in the bladder suprapubically.

***SUPRAPUBIC INCISION FOR REMOVAL OF STONES***

Perform an extra-peritoneal suprapubic cystotomy. The extra-peritoneal approach is preferred because a bladder with a stone in it always has high levels of bacterial contamination. Avoiding entry into the peritoneal cavity is a crucial step in preventing serious post-operative morbidity.

- Fill the bladder with 500 ml via Foley. If this is not possible because the stone is large and obstructing the Foley, ask an assistant to push the stone up vaginally which makes it easy to feel the bladder and stone abdominally.
- Make a transverse incision in the midline, close to the symphysis. If you stay close to the bone, you will stay extra-peritoneal and not accidentally injure bowel. Use a self-retaining retractor or two small retractors to keep the recti muscles apart. Avoid opening the peritoneal cavity - if you open it, close it before you open the bladder.

**! Tip!** If you dissect between the rectus tendons, just above the symphysis you can almost always enter the retropubic space without entry into the peritoneum. The medial aspects of the tendons can be divided (for 1-2 cm on each side) safely without compromising the rectus abdominis function. Once you separate the rectus tendons medially, you can incise the inferior, posterior rectus sheath in a transverse direction just above the symphysis. Usually, you are then in the retropubic space (peri-vesical fat and blood vessels are seen). You can bluntly dissect the bladder off the pubis posteriorly to allow the bladder to drop a bit. The stone can be pushed up to identify the bladder wall or you can try to lift the Foley balloon with your fingers.

- Insert two stay sutures in the bladder on either side of where you are going to make your incision or grasp the bladder wall with two Allis clamps.
- Make a longitudinal opening in the bladder in the midline between the sutures or Allis clamps. You then extend the bladder incision bluntly. Remove the stone. Once the stone is removed, the bladder is flushed extensively with saline.
- Close the bladder in two layers (mucosal layer and detrusor layer) to ensure proper watertight closure.
- The risk of wound infection is high, so only close the skin with 1-2 interrupted sutures and/ or place a drain.
- If urine leaks from the wound: check that the Foley catheter is not blocked. Sometimes the whole incision (skin, sheath and bladder) breaks down. Just keep the Foley in place and it will all heal eventually.

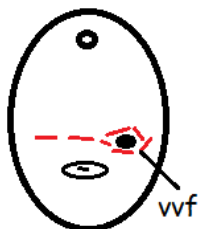### REMOVAL OF STONES AT THE SAME TIME AS VVF REPAIR (VAGINAL INCISION)

If the stone is big and the fistula is small, you can enlarge the fistula transversely by incising through the anterior vagina into the bladder, remove the stone and do a repair. The advantage is that it avoids an abdominal wound and may sort out the stone and fistula in one operation.



This technique is only appropriate in some cases (especially more proximal fistulas) as otherwise you may create more damage. However, it is useful for all to know the principles of the technique in case you encounter a stone unexpectedly during a repair. If performed electively, it should be by an experienced surgeon.

- *If there is a (small) fistula*, make a transverse incision through the fistula to open the bladder further and remove the stone (Fig. 3.11c). Some surgeons prefer a vertical incision through the fistula as the risk of cutting the ureters should be less. What you do next is only a guide:
  - If the bladder is healthy enough (i.e. the tissues will hold the sutures) and the urine is clear or only slightly turbid, do a full repair in the same session i.e. close the bladder leaving the anterior vagina open as much as possible. In the presence of infection, only adapt the anterior vagina wall with a couple of sutures. I would stitch any lateral incisions made as these are often vascular. Leave the catheter in at least 18 days.
  - If the bladder is not healthy enough to attempt closing (i.e. tissues friable or very thin) or the urine is cloudy or purulent, without further dissection, only adapt the anterior vagina wall with everting interrupted 2-3 vertical mattress sutures leaving the bladder untouched so that infected urine can drain out via the catheter. By leaving the catheter (16F) in for at least 14 days and up to 28 days, the bladder will heal in about 60% of cases (Kees Waaldijk's series unpublished). If there remains a residual fistula, it is closed in a second attempt.
- *If there is no fistula or the fistula has healed:* I would prefer to use the suprapubic approach rather than risk creating a new fistula by doing a vaginal approach.



*Case history:* A patient with a history of one previous VVF repair five years previously, presented with large bladder stones and a pinhole juxta-cervical VVF. A wide transverse incision was made through the fistula (see Fig. 3.11c). Two large 4 cm stones were removed vaginally. Both ureters were visualized away from the edges of the fistula. The bladder was closed in one layer of interrupted sutures. The vagina was closed only with two angle sutures with the rest left open. The VVF healed although it required prolonged catheter drainage in the prone position in a very compliant patient.

Fig 3.11c: Shows the incision made to remove the bladder stones.

### (3.6) DOUBLE VVFs

If there are two separate VVFs, then:

- If the two are close together, it may be easier to join them together and then repair. However, do not be in a hurry to join two holes together as you may end up with one large but difficult to close fistula. If you are unable to catheterize the ureters, it may be easier to join the fistulas together so that you have a bigger opening. However, be careful when dividing the bridge between them in case the ureter is in it.

- If there are two small juxta-urethral residual fistulas, it is often a good idea to join them together as they were probably one initially. If there are two separate lateral/ corner fistulas: see section 3.8 and Fig. 3.17b.
- If the two fistulas are wide apart, it is better to close them separately e.g. Fig. 3.13c.

**Dissecting off the vagina:** Even if you are closing the fistulas separately, it is a good idea to mobilize the vagina off both, prior to closure to improve exposure (see Fig. 3.13a).

- Make the incision around the proximal fistula and mobilize the vagina.
- Make an incision around the distal fistula and mobilize the vagina.
- Complete the mobilization of the vagina off the bladder. You may split the vagina in the midline to join the two incisions. You should now be able to see the bladder exposed and both fistulas.

**Closure of fistulas:** With the vagina dissected and both fistulas exposed, it is easier to decide how to close them. If you just close one fistula without considering the second, it may then be difficult to close the second leading to too many sutures with ischaemia and tension on the repair of the first fistula. Even if the two fistulas appear to be far apart initially, they will end up very close together by the time you have finished closing them.

Therefore never finish closing the proximal fistula without considering how you will close the distal one. There are two options:

- *If close together*, close them together: The sutures used to close one fistula can also be used to close the second one as shown in Fig 3.13b.
- *If there is a reasonable distance between them*, close them separately: Consider closing the proximal fistula longitudinally and the distal one transversely as shown in Fig. 3.13c. In this way, closure of one will not interfere with the other.


Sometimes you only discover the more proximal fistula after closing the distal one. In this case, if you want to close the proximal one transversely, you may have to remove some of the sutures from the distal fistula so the two fistulas can be closed together. Otherwise, you may cause ischaemia with too many sutures.

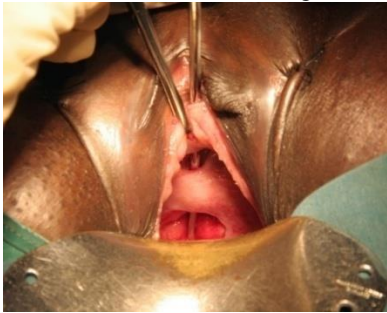

Fig. 3.12: Shows two fistulas.

The key points in managing multiple fistulas are:

- First, separate the vagina off both fistulas before you decide how to close them.
- Never close one fistula without considering how you are going to close the other fistula.
- If closing the fistulas separately, I prefer to start with the proximal one as I find access is easier doing it this way.



Make sure you do not mistake the two ends of a circumferential defect for two separate fistulas. Always check with the metal catheter to see how they relate to each other.

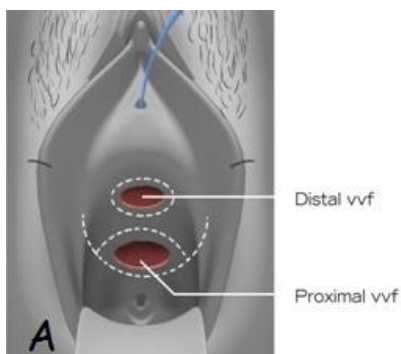


Fig. 3.13a: Shows the initial incision around both fistulas.

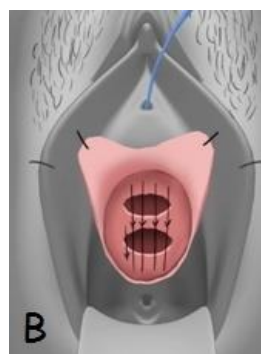

Fig. 3.13b: Shows the two fistulas being closed together.

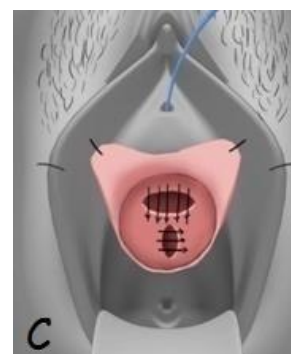

Fig. 3.13c: Shows the two fistulas closed separately.



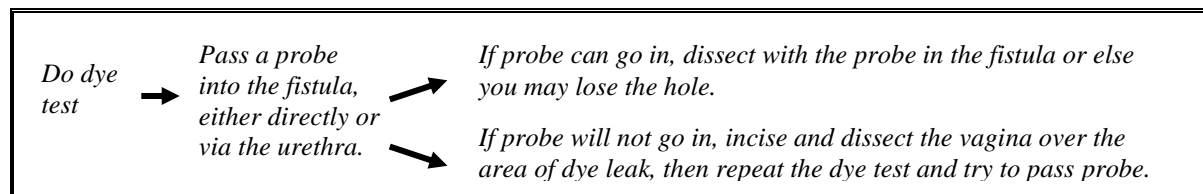
**Tip!** If there is a large VVF and a second smaller VVF in the urethra, consider doing a staged repair i.e. repair the urethral defect later. This is because the urethra may slough if you try to close both fistulas at the same time.

### (3.7) PINHOLE FISTULAS FOLLOWING PREVIOUS REPAIRS

**(Step 1) Finding the hole and inserting a probe:**

- It is often necessary to inject dye into the bladder to confirm the site of the fistula. Once found, saline can be used instead of dye to pinpoint the exact site while avoiding tissue staining.

- Sometimes when you have difficulty finding the fistula with the dye test, rather than keeping injecting dye, it may help to empty the bladder and start again.
- There may be more than one fistula track in these cases. Sometimes there are multiple holes in the vagina but they all connect with one hole in the bladder (sometimes called the watering-can effect).
- You cannot usually see the bladder mucosa through the fistula but if a probe can be passed through the fistula and this connects (metal on metal) with the metal catheter in the bladder, this is sufficient to identify the fistula (see Fig. 3.14a).



**! Tip!** In these fistulas, it is very important to leave an island or large rim of vagina (0.5 – 1 cm) around the fistula so that you can identify the fistula later when the dissection is finished.

**STOP** If the probe goes into the pinhole but does not connect with the metal catheter in the bladder, the probe may be going into a ureter. Repeat the dye test. If the urine from the pinhole is clear = ureter is outside the bladder from a previous repair. See chapter 9 for management of such cases.

**(Step 2) Dissection:**

Even though the fistula is small, you still need a wide exposure to allow proper closure (see Fig. 3.14b). Make a transverse, cruciate or inverted U incision in the vagina across the fistula. It helps to keep the probe in the fistula as long as possible to help identify it as you dissect widely. The probe also acts as a retractor as you make your incision around the fistula opening. If you cannot pass the probe in, you can still dissect.

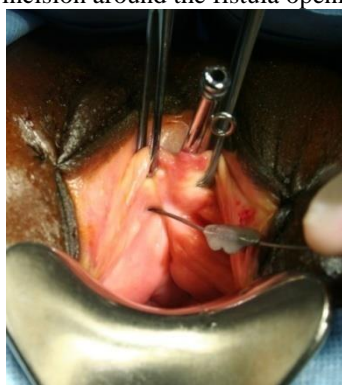

Fig. 3.14a: Identification of VVF with a probe.

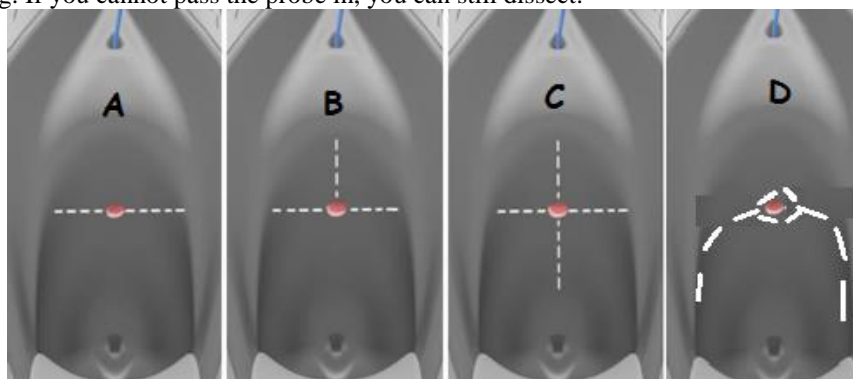


Fig. 3.14b: Shows the various incisions that can be made. Longitudinal incisions are against the natural tissue forces so transverse ones are better.

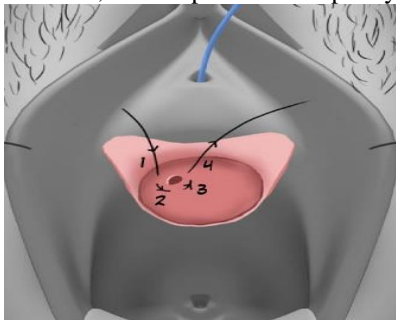
- Dissect as for any fistula staying close to the vagina. Usually in these cases, it is only possible to hold the vaginal edges and it is difficult to hold the bladder edges. The bladder is therefore retracted by the probe, which is pulled in various directions, depending on where you are dissecting.
- In larger fistulas, you can use a metal catheter or a Hegar dilator as the probe. The vagina is dissected off the bladder with a knife or scissors.
- After mobilizing the vagina, you are left with an island of vagina around the fistula, which is excised later. The island of skin prevents you from losing sight of the fistula which happens easily as the fistula is so small. With small fistulas, it is difficult to look for the ureters but at least make sure that the ureters are not in the edge of the fistula.

Note: Initially it may not be possible or necessary to hold the bladder edges with Allis forceps. However, it may be possible later and you may remove the probe/ dilator and hold the bladder edge with an Allis.

**! Top Tip!** There is often a lot of scar tissue in these fistulas, and it can be difficult to identify the margins of the bladder/ fistula. Scar tissue is hard whereas the bladder is soft. Continue excising scar until the edges are soft and pliable. When you have achieved this, it means you can close the fistula edges. If you just suture scar tissue together, it will not heal. Do not be worried about making the fistula slightly bigger in the process. Reminder: Hard tissue near the fistula = scar or cervical tissue. Firm tissue = vagina. Soft tissue = bladder.

**(Step 3) Closure:**

With the probe in the fistula, place several interrupted sutures and tie when all are placed (recommended). In very scarred cases, an interpositional flap may be considered.



If access is difficult, another option is to place a mattress or a purse-string stitch while the probe is in the fistula (see Fig. 3.15). In this situation, 3-4 bites are taken. If possible, the initial suture can be through the periosteum but this depends on the fistula site.

*Fig. 3.15: The first bite (1) is taken through the periosteum. Then the fistula is closed with a purse-string (circular) suture.*

**Tip!** If you fail to pass the probe into the area of dye leak or if you pass it but it fails to connect with a metal catheter passed from the urethra, then it is likely that you have not identified the fistula site. Usually, there is a track coming from the fistula so you need to excise more scar tissue and try again. Only when the probe touches the metal catheter can you be confident that you have reached the fistula site. However, with very small fistulas the probe may not enter the fistula.

**Tip!** A good rule is that when you have excised sufficient scar tissue around the fistula track, you should see a good flow of dye coming through the fistula instead of the initial small leak.

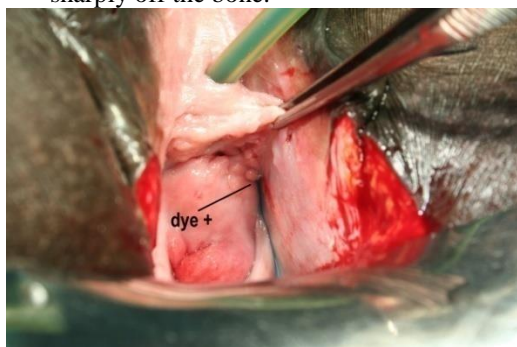
### (3.8) AROUND THE CORNER FISTULA

If a fistula occurs laterally e.g. following a previous failed repair, then access can be difficult as these fistulas are always densely adherent to the underlying bone. The best way to tackle this is to mobilize out laterally by opening the para-vesical space so that the defect becomes more medial.

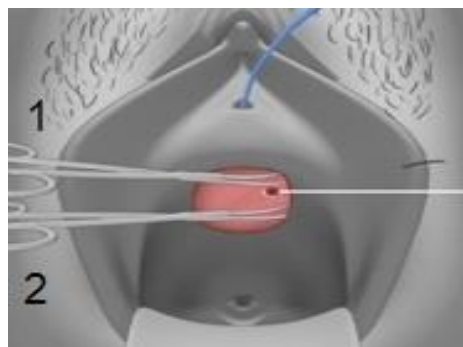
**(Step 1) Dissect vagina:** For good exposure of the bladder, a wide transverse incision can be made which is extended out laterally. Stitch back the distal flap.

**(Step 2) Mobilize bladder:** After dissecting the vagina off, either sharply dissect the bladder off the pelvic side-wall or use the “blast and spread” technique to mobilize the fistula (Fig. 3.16b):

- Pass the scissors tips closed through the fascia and close to the bone proximal to the fistula, using a sharp tap on the scissors (blast = scissors 2). Then spread the tips until you can get your finger in.
- Repeat this distal to the fistula (scissors 1). Be careful not to go too deep with the scissors to avoid causing deep bleeders. You are now left with the area of the fistula still attached to the bone.
- Then using a finger-tip above and below the fistula, pull medially on the bladder and dissect the fistula sharply off the bone.



*Fig. 3.16a: Shows a typical lateral recurrent fistula.*



*Fig. 3.16b: The blast and spread technique.*

**(Step 3) Bladder Closure:** Place several interrupted sutures. Place all the sutures first before tying. Use the first/previous suture (on artery forceps) as a retractor while you place the second/next. The direction in which you place the sutures depends on the individual case. You may take the bites lateral to medial, or medial to lateral, or distal to proximal.

- As access is difficult, using a small J needle 22 mm (Vicryl W9223) or a 17 mm needle can be very useful. However, a 5/8 circle 26 mm needle may allow better bites of tissue and is usually the best one to use.
- Check with dye that there is no leak.

**Tip!** If after mobilization and when you are ready to start closure, the bladder edges do not come together easily, to free the lateral fistula edge more, you can incise into the bladder muscularis 1-2 mm deep to

gain extra mobility. This should be done several centimetres back from and parallel to the (lateral) fistula edge for approximately 1-2 cm in length. Pull the bladder medially and feel the tension. As you cut with the scissors or knife you will feel the bladder edge coming in. In reality, you are often cutting into scar tissue on the outside of the bladder rather than bladder muscle. Be aware of where the ureter is when you are going to do this. This useful tip can be applied to any type of fistula where you need some extra mobility and is not specific to this type of fistula although this is where it would be most commonly needed.

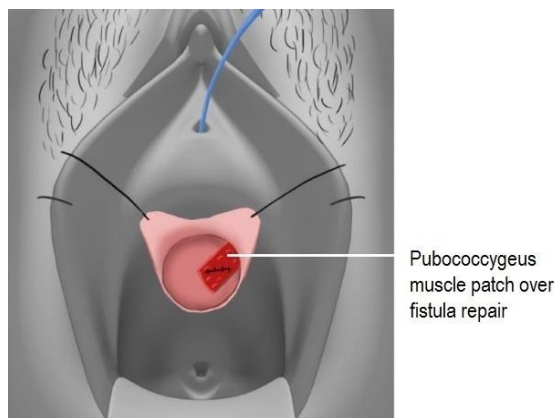
**(Step 4) Intermediate layer:**

Try to get tissue over the repair to reinforce it as these fistulas often break down. This can either be with:

- Pubo-cervical fascia: if there is no obvious fascia laterally, try to develop a layer of it by freeing it from the proximal flap of the vagina near to the cervix.
- Pubo-coccygeus (levator ani): take a piece of muscle off the lateral side of the pelvis at whatever level is most accessible to the repair – the same place where you get the pubo-coccygeal sling (see chapter 1 Step 4). The patch is started proximally and freed so its base is distal. Hold with an Allis proximally as you develop the flap. You can then swing it in over the repair. Stitch it in place so that you get a watertight closure.
- Martius or Gracilis flaps are options. If you place a Gracilis flap over the repair, take it from the side opposite the fistula as this will fit in more easily than if you take it from the same side. It is easy to place the tendon end of the Gracilis over the repair.
- Very occasionally, to reinforce a weak repair, the bladder can be sutured to the lateral pelvic side-wall (see chapter 1c: step 3: If the dye test remains positive).



**Top Tip!** A muscle patch can be used in any situation where you have a leak on the dye test but you think another stitch would make it worse. Put the patch over and then stitch it in so the repair is watertight.



Repairs of lateral recurrent fistulas have a high failure rate. However, if you take the following steps, failure rates should be low:

- Adequate mobilization by opening para-vesical space so that the fistula comes in medially.
- Adequate removal of scar tissue so that you see the fistula clearly.
- If the edges do not come together easily, incise into the bladder muscularis for 1-2 mm deep to gain extra mobility.
- After the repair, get an intermediate layer over the repair: pubo-cervical fascia or pubo-coccygeus or Gracilis muscle or Martius flap.

Fig 3.17a: Shows a patch of levator ani (pubo-coccygeus) freed to be used to reinforce the repair.

**ADDITIONAL OPTIONS FOR MANAGING DIFFICULT LATERAL FISTULAS:**

Lateral fistulas are often the result of a failed repair of a circumferential defect.

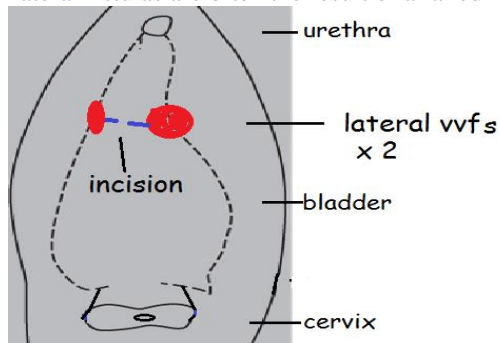


Fig. 3.17b: Shows two lateral fistulas and the incision (blue line) joining them.

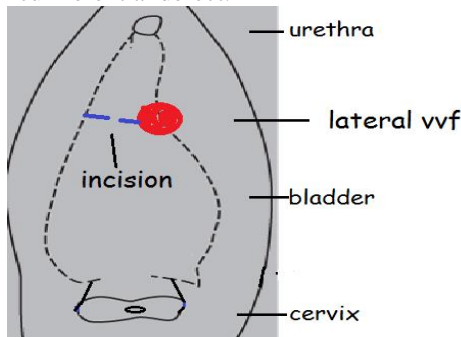


Fig. 3.17c: Shows one lateral fistula and the incision (blue line) to open the urethra/ bladder junction.

**Option 1: Joining up two lateral fistulas:** In this situation, all or most of the fistula(s) is visible (Fig. 3.17 b).

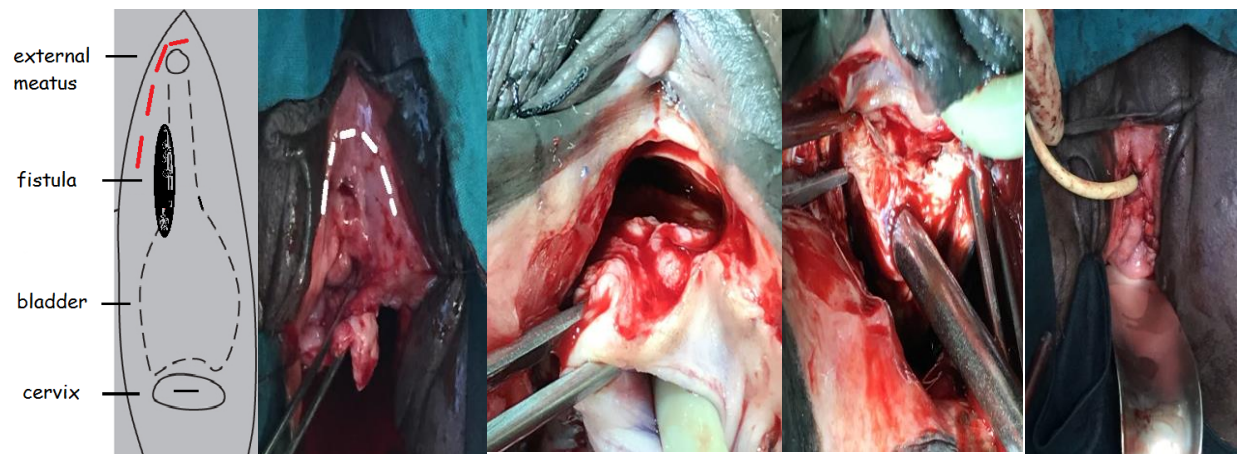
- If there are lateral fistulas on both sides (Fig. 3.17b), it may be easier to join the two holes by cutting the posterior bladder wall which separates the two holes. This is particularly useful if one or both of the fistulas

extends around laterally like a  $\frac{3}{4}$  circumferential fistula. Once you have joined the two fistulas, you can get a clear view and access to both fistulas. The anterior part of the repair is usually intact (i.e. the 11, 12 and 1 o'clock positions although you can do a full circumferential dissection if this makes for a better and easier repair. You have to close the defect laterally and posteriorly like for a  $\frac{3}{4}$  circumferential fistula.

- Even if there is only one difficult fistula (Fig. 3.17c), it may still be necessary to open the whole (posterior) junction of the urethra and bladder to access the fistula.

**Option 2: Supra-meatal approach:** In some cases, the posterior bladder/ urethra has healed but there is still a defect anteriorly on one or both sides at the urethro-vesical junction. Part of the fistula may be visible although more commonly all you see is dye leaking on one or both sides, and the fistula is not visible or accessible. In this case, a supra-meatal approach is a useful way to access these otherwise inaccessible fistulas. *Method* (see Fig. 3.18): Incise around the top of the urethral meatus just below the pubic bone i.e. an inverted U incision between 3 and 9 o'clock positions. However, you can sometimes manage with a more limited incision on the affected side as shown in Fig. 3.18a. Incise enough to visualize the fistula.

- With sharp and blunt dissection, the urethra and distal bladder are freed from the pubic bone. The fistula is now easily visualized with the help of a dye test if necessary and a good repair can be performed.
- If the urethra tears during dissection/ mobilization, then there probably was a circumferential defect with the urethra stuck to the bone. In this case, you have to mobilize the bladder anteriorly to bring it down so the defect can be closed.
- It is a good idea to place a Martius flap over the repair
- The one disadvantage of this incision is that it loosens the anterior fixation of the external urethral opening from its almost immobile/ fixed position which is required for the urethra to keep its length.



*Fig. 3.18a: Shows a fistula involving the antero-lateral urethra and distal bladder. The supra-meatal incision is the red interrupted line.*

*Fig. 3.18b: The initial dissection has been made which failed to give access to the fistula. The dotted white line is the supra-meatal incision which is about to be made.*

*Fig. 3.18c: Shows the supra-meatal incision made with the Foley catheter in the external meatus and most of the urethra is now freed from the pubic bone on the right side.*

*Fig. 3.18d: Shows a metal catheter in the fistula on the right lateral side with the Foley catheter (just visible) in the external meatus which is swung up and over to the left.*

*Fig. 3.18e: Shows the incision in the vagina closed with the urethra back in place. The Foley catheter is inserted in the external meatus.*

**Option 3: Suprapubic approach:** If the fistula is both high and lateral, it may not be possible to get access to close the defect and a suprapubic approach will be necessary (see section 5.3d). However, using the supra-meatal approach, one can usually avoid the suprapubic approach for lateral or antero-lateral fistulas.

### (3.9) GENITAL FISTULAS FOLLOWING RADIOTHERAPY

Radiotherapy-induced fistulas are seldom if ever associated with spontaneous closure (i.e. even with the help of a Foley catheter) and operative management should be performed as appropriate. However, repair should not be attempted until at least one year after the completion of radiotherapy. There are four options in managing these cases:

- Conventional repair: these should always be performed with a flap to bring in fresh blood supply. The only radiotherapy induced VVFs or RVFs that I have managed to close successfully were performed with the



help of a Gracilis or rectus flap. Mobilization of the fistula is often difficult and the edges are more likely to slough. After repair of VVF, the Foley catheter is left in for 28 days. If a ureter needs re-implantation, then the ureteric catheter is also left in for 28 days.

- Colpocleisis is a good option especially if the lower vagina appears healthy (see below).
- Diversion (urinary = Mainz pouch or ileal bladder; faecal = colostomy) is another option because even with good technique, healing is unlikely.
- In RVFs, it is possible to do an anterior resection and then pull through healthy colon and do a low colo-anal anastomosis from below (as described in chapter 7).

**! Tip!** It is a good idea to do an examination in the operating room before any surgery to assess the defect. Give frusemide to locate the position of the ureters as they are often outside the bladder.

**COLPOCLEISIS:** In patients with VVF, or VVF with RVF, it may be possible to close off the vagina (colpocleisis). By closing the vagina away from the irradiated area, and in tissues with better blood supply, it means that healing is more likely. However, in some cases, the whole vagina has been radiated and the tissues may still fail to heal. If the vagina looks pale, then it is worth attempting colpocleisis. If it appears like slough tissue, then it is probably not worth attempting. The effects of a colpocleisis are:

- If there is a VVF, the upper vagina is made into a diverticulum of the bladder (see Fig. 3.19).
- If there is a combined VVF and RVF, the urine drains via the VVF into the upper vagina, and then via the RVF into the rectum.

**Method:** A circumferential incision is made 1-2 cm below the level of the fistulas and as far as possible on healthy tissue. By dissecting upwards, the cut edges of the vagina around the fistula are turned inwards by a single layer of sutures. By dissecting downwards, a lower sleeve of vagina is made. Part of this can be excised but leave sufficient flaps for the lower vagina to be closed. (Alternatively two circular incisions can be made at as high a level as possible, the second one situated one centimetre below the first. The intervening vaginal wall is then excised.) The bare para-vaginal tissues are approximated transversely (by approximating the anterior and posterior walls) in as many layers that can be achieved without tension. Aim for a minimum of four rows of interrupted sutures and sometimes several more (Fig. 3.19a). A flap is placed e.g. Martius or Gracilis. The flap is used as there is inevitably some space remaining here (Fig. 3.19b). Usually, the only closure below the flap would be a single layer of interrupted sutures in the vaginal or vulval skin of the introitus i.e. just proximal to the external meatus (Fig. 3.19c).

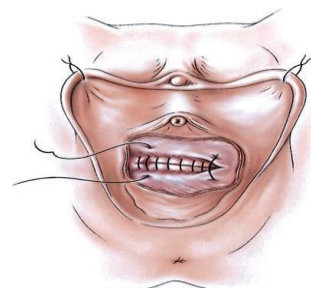

Fig. 3.19a: Colpocleisis being performed in several layers transverse front-to-back.

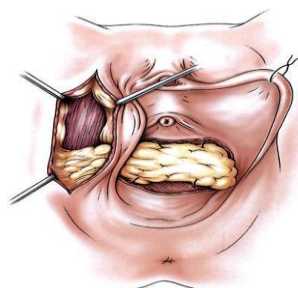


Fig. 3.19b: Shows a Martius flap being used to fill the dead space.

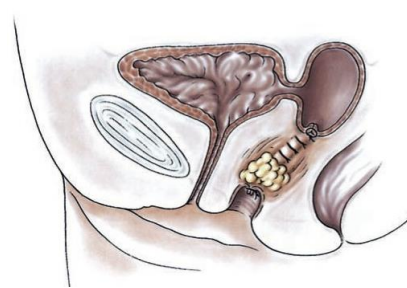


Fig. 3.19c: Shows the colpocleisis completed. Courtesy of Paul Hilton.

**Specific complications:**

Generally, colpocleisis is a safe and straightforward procedure and is well accepted provided the patient and her partner are prepared to accept the loss of sexual function. Nevertheless, there are two important complications:

- The effects of irradiation are life-long; post-radiotherapy fistulas may present many years (up to 50 years) after treatment. Because of this, even if at presentation only a VVF is seen, and even if the patient appears to be cured by colpocleisis, an ‘RVF’ may develop later (between the rectum and the ‘obliterated’ upper vagina). In such cases, the development of leakage of urine per rectum may occur as a late complication, in an apparently closed fistula.
- Because the effect of the procedure is to obliterate the vagina by approximating the anterior and posterior walls, if the closure is made too low, the urethra may in effect be pulled open, increasing the risk of post-repair stress incontinence. The risk may be reduced to some extent by using an interpositional flap (e.g. Martius or Gracilis) to fill in dead space and provide some additional urethral support.